CDX-2 Homeobox Gene Product Expression in Neuroendocrine Tumors

Its Role as a Marker of Intestinal Neuroendocrine Tumors

Mattia Barbareschi, MD, Claudia Roldo, MD,† Giuseppe Zamboni, MD,‡ Paola Capelli, MD,† Alberto Cavazza, MD,§ Ettore Macri, MD,¶ M. Giulia Cangi, PhD,‖ Marco Chilosi, MD,† and Claudio Doglioni, MD‖*

Abstract: CDX-2 is a homeobox gene product essential for intestinal development and differentiation. It can be used as a specific marker of colorectal adenocarcinomas and other tumors with intestinal differentiation, but little is known about its expression in endocrine and neuroendocrine (NE) cells and NE primary and metastatic tumors. Using the Cdx-2-88 monoclonal antibody, we evaluated CDX-2 expression in routine samples of 20 normal endocrine/NE tissues and of 299 samples of well-differentiated NE tumors (WDNET) and high-grade NE carcinomas (NEC) from different sites. For 17 cases, we examined primary and corresponding metastatic lesions. We also examined 8 cytologic samples of liver metastases derived from 4 ileal WDNETs, 1 lung WDNET, and 3 pancreatic endocrine tumors. CDX-2 mRNA expression with RT-PCR technique on frozen material was evaluated in 5 WDNETs. CDX-2 was expressed in normal NE cells of the intestine and gastric fundus. High CDX-2 expression was seen in all ileal and appendiceal WDNET, while low levels were seen in WDNETs from stomach, duodenum, and rectum; no reactivity was seen in other WDNETs. Low levels of CDX-2 expression were seen in one third of nonfunctioning pancreatic WDNET where it was more frequently observed in cases with metastatic disease ($P = 0.002$). CDX-2 was identified in all cytologic specimens of metastatic ileal WDNETs. CDX-2 mRNA analysis confirmed immunohistochemical results. CDX-2 was expressed at high levels in 81% of intestinal NEC. Unexpectedly, variable levels of expression of CDX-2 were seen also in 39% of NEC of other sites, without any relation with the site of origin. This reactivity frequently overlapped TTF-1 expression, suggesting deregulated expression of homeobox genes in NEC. The restricted pattern of CDX-2 expression may have diagnostic value in the identification of the primary site of a metastatic WDNET. Conversely, a limited diagnostic role is suggested for CDX-2 in NEC because of its frequent expression in nongastrointestinal tumors.

Key Words: CDX-2, immunohistochemistry, neuroendocrine, human neoplasms, diagnostic marker

(*Am J Surg Pathol* 2004;28:1169–1176)

From the *Department of Histopathology, S. Chiara Hospital, Trento; †Department of Pathology, University of Verona Verona; ‡Department of Pathology, University of Verona and S. Cuore-Negrar; §Department of Histopathology, Arcispedale S. Maria Nuova, Reggio Emilia; ¶Department of Histopathology, S. Martino Hospital, Belluno; and ‖Department of Histopathology, S. Raffaele Hospital, Milano, Italy.

Supported in part by grants of Italian Ministry of Health, Ricerca Finalizzata 2002-2004, ORSA Association, MIUR, Rome, and Associazione Italiana Ricerca Cancro, Milan, Italy, and Fondazione Cariverona (Bando 2001), CNR-MIUR Diagnostica Molecolare in Oncologia, and European Community QLG1-CT-2002-01196.

Reprints: Claudio Doglioni, MD, Department of Histopathology, S. Raffaele Hospital, 20132 Milano, Italy (e-mail: claudio.doglioni@hsr.it).

CDX-2 is the product of the *Cdx-2* homeobox gene related to the *Drosophila melanogaster* gene *caudal* which is essential for the axial patterning and intestinal development of the fruit fly. Three *Cdx* homeobox genes have been identified in mice (*Cdx-1*, *Cdx-2*, and *Cdx4*), and two have been identified so far in humans (CDX-1[4] and CDX-2[8]). These genes encode for transcription factors that play an essential role as regulatory proteins for proliferation and differentiation of intestinal epithelial cells in fetal as well as in adult tissues.[5] CDX-1 and CDX-2 are lineage specific: in normal adult human tissues, they are expressed only in colonic and small intestinal epithelium and regulate the expression of several different genes involved in intestinal cell differentiation and metabolism.[14,22] CDX-2 is a very specific and sensitive marker of colorectal adenocarcinomas,[12] which can be used in the differential diagnosis of metastatic adenocarcinomas of unknown primary sites.[2,23]

Well-differentiated neuroendocrine (NE) tumors (WDNET) are relatively common neoplasms arising mainly in the lung, gastrointestinal tract, and pancreas. WDNETs are able to metastasize to liver, lymph nodes, or other organs. Since WDNETs share similar morphology and overlapping immunohistochemical profiles, these features are not useful for determining the site of origin of a metastatic lesion. Identifying the primary site of WDNET has significant clinical and therapeutic relevance. Similar considerations apply also for

high-grade NE carcinomas (NECs). In this context, TTF-1, another homeobox gene, has been proposed for the identification of metastatic lung NE tumors.[6,16] The possible role of CDX-2 in promoting endocrine differentiation in intestinal epithelial cells and its expression in intestinal NE cells has not been investigated. CDX-2 expression has indeed been described in a limited series of NE intestinal neoplasms, but little information is available about its expression in other NE tumors.[15,23]

In the present study, we evaluated CDX-2 expression in a large series of common and uncommon NE human tumors of different origin, both primary and metastatic as well in normal endocrine cells in different tissues. Our aims were: 1) to evaluate CDX-2 expression in normal intestinal endocrine cells, 2) to delineate the pattern of CDX-2 expression in NE tumors from different sites, and 3) to verify if CDX-2 can be used as a marker in the differential diagnosis of metastatic NE tumors.

MATERIALS AND METHODS

Cases

Twenty samples of formalin-fixed, paraffin-embedded normal endocrine/NE tissues, including hypophysis, thyroid, parathyroid, gastrointestinal and lung tissue, pancreas, paraganglia, adrenal gland, ovary, and testis, were evaluated. A total of 299 cases representative of most NE tumors of different sites, including primary and metastatic lesions, were retrieved from the files of the Departments of Pathology of Belluno, Reggio Emilia, Verona, and Trento. All cases had been previously characterized for NE phenotype and, for pancreatic lesions, for hormone production.

A detailed list of the investigated tumors is shown in Table 1. In 17 cases, metastatic and corresponding primary NE tumors were available: this series included 11 liver, 5 nodal, and 1 mammary metastases, deriving from lung small cell carcinoma (1 case), lung WDNET (1 case), ileal WDNET (6 cases), gastric and duodenal gastrinomas (2 cases), pancreatic WDNET (6 cases), and poorly differentiated (1 case) NEC.

The 61 pancreatic tumors were classified as functioning (13 cases) and nonfunctioning (48 cases) on the basis of hormone production: 9 cases were positive for insulin, 2 for glucagon, 1 for serotonin, and 1 for multiple hormones. The clinical stage was known in 50 of these cases: 19 presented with metastases and 31 without. For each case, one representative paraffin block was selected and 5-μm sections were cut.

TABLE 1. CDX-2 Expression in NE Cells and Primary WDNET of Different Organs

		CDX-2-Positive			
Organs and Tumors	**Total No. of Cases**	**No. of Cases**	**Intensity Range**	**% of Positive Cells (range)**	**Pattern of Staining**
Lung					
Tumorlet/NE hyperplasia	5	0			
WDNET	30	0			
Stomach					
NE hyperplasia	5	3	1–2	30–40	N
WDNET	5	5	1	20–80	N
Duodenum					
WDNET	4	4	1–2	40–70	N
Ileum					
WDNET	14	14	3	90 –100	NC
Pancreas					N
Functioning tumors	13	0			
Nonfunctioning tumors	48	14	1–3	5–90	N
Appendix					
WDNET	6	6	2–3	80–90	NC
Colon					
WDNET	1	0			
Rectum					
WDNET	9	7	1–3	40–90	NC

N, nuclear reactivity; NC, nuclear and cytoplasmic reactivity.

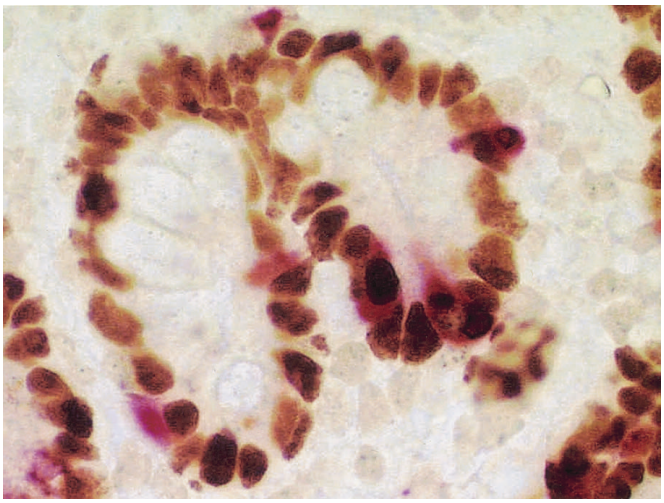

FIGURE 1. Double immunostaining for CDX-2 (brown) and chromogranin A (red) in normal small intestine. NE cells show strong chromogranin stain in the cytoplasm and CDX-2 immunoreactivity in the nucleus. All other enterocytes present CDX-2 immunoreactivity in the nucleus.

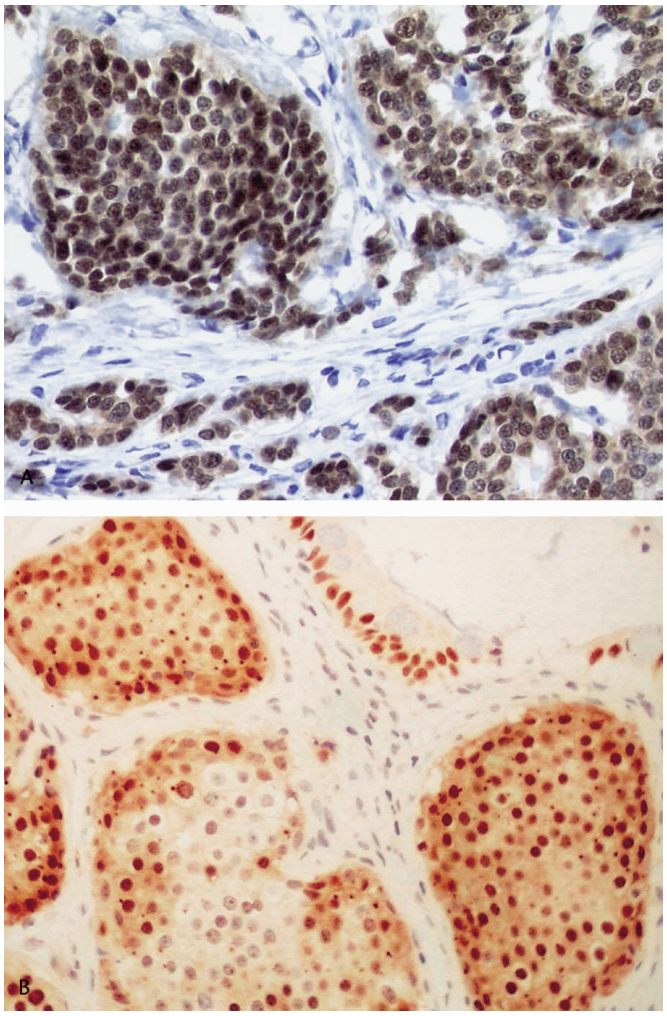

FIGURE 2. CDX-2 immunoreactivity in ileal WDNETs. In most cases, ileal WDNETs show strong nuclear staining with minor degrees of cytoplasmic staining (A); rare cases may also show a dot-like paranuclear reactivity pattern (B).

We also examined a series of eight cytologic samples obtained by fine needle aspiration of liver nodules, for which surgical resection specimens were available and for which an unequivocal diagnosis was established. The liver metastases were derived from ileal WDNETs (4 cases), lung WDNET (1 case), and pancreatic endocrine tumors (3 cases).

Five cases of WDNET (2 ileal, 2 pancreatic, and 1 pulmonary) for which frozen material was available were also evaluated for CDX-2 mRNA expression, with an RT-PCR technique. One case of colonic carcinoma was used as positive control.

Immunostaining

All cases were immunostained with a StreptABC technique using a monoclonal antibody against CDX-2 (Cdx-2-88, Biogenex, San Ramon, CA, 1:200 dilution).[2] Samples of normal ileal and colonic mucosa were submitted to double immunostainings for chomogranin A (LH2H10, Labvision, Fremont, CA) and CDX-2, using a previously described procedure.[3] Selected cases of high-grade NE tumors were also immunostained for TTF-1 (8G8G3/1, Labvision, Fremont, CA). Heat-induced antigen retrieval was performed using citrate buffer in a microwave oven. Primary antibody was detected using a sensitive Strept-ABC technique with diaminobenzidine development.[3] All stainings were performed with an automatic immunostainer (Biogenex Optimax). Appropriate positive and negative controls were run simultaneously. Papanicolaou stained cytologic samples were bleached, subjected to heat-induced antigen retrieval, and immunostained. Immunostaining was scored semiquantitatively according to the estimated percentage of positive tumor cells, ie, 0 (no staining), 1 (1%–10% reactive cells), 2 (11%–50%), and 3 (51%–100%). Intensity (weak, +; moderate, ++; intense, +++) and pattern (cytoplasmic/nuclear) of staining were also recorded.

RNA Extraction and RT-PCR for CDX-2

Frozen samples were ground by a tissue dismembrator (Mikro-Dismembrator S, B. Braun International, Germany) and RNA were extracted using a guanidine isothiocyanate protocol (TRIzol Reagent GIBCO BRL, Life Technologies, Gaithersburg, MD). Following DNAse treatment, equal amounts of total RNA (1 μg) were reverse transcribed into cDNA using random primers and Superscript First-Strand Synthesis System (GIBCO BRL, Life Technologies) according to manufacturer's instructions. The human Gsα gene was used as endog-

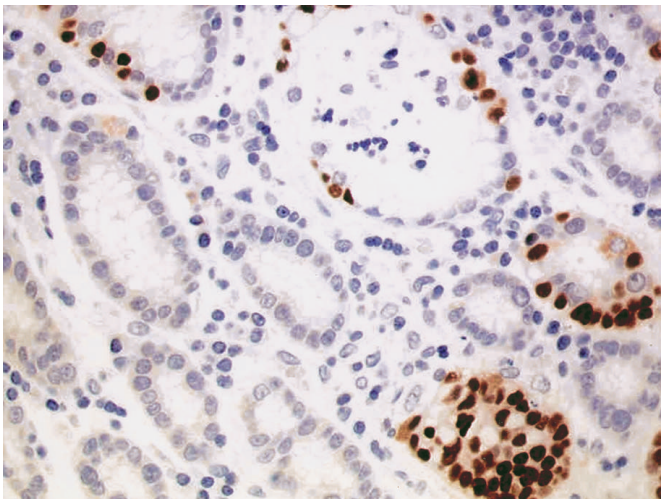

FIGURE 3. Gastric NE cell hyperplasia. In this case hyperplastic NE cells show a distinctive nuclear CDX-2 immunoreactivity.

enous control. PCR for CDX-2 and Gsα was performed in 25 μL reaction mixture containing DNA template, PCR buffer (50 mM KCl, 10 mM Tris-HCl, pH 8.3), 1.5 mM $MgCl_2$, 200 mM of each dNTP, 0.4 mM of each primer (human CDX-2 upstream primer 5′-TGGAGCTGGAGAAGGAGTTTCA-3′, downstream primer 5′-ACAGAGCCAGACACTGAGGCTT-3′; human Gsα upstream primer 5′-GTGATCAAGCAGGCT GACTAT-3′, downstream primer 5′-GCTGCTGGCCAC-CACGAAGATGAT-3′), and 0.5 unit TaKaRa Taq DNA polymerase (Takara Shuzo CO, LTD, Japan). Touchdown PCR 65°C to 55°C consisting of one cycle at 95°C (5 minutes), 10 touchdown cycles at 94°C (30 seconds), 65°C (30 seconds) with a decrease of 1°C each cycle, and at 72°C for 30 seconds, and followed by 20 cycles of 94°C (30 seconds), 55°C (30 seconds), and 72°C (30 seconds), with a final extension at 72°C for 7 minutes was performed. The resulting amplification products were then analyzed by agarose gel electrophoresis.

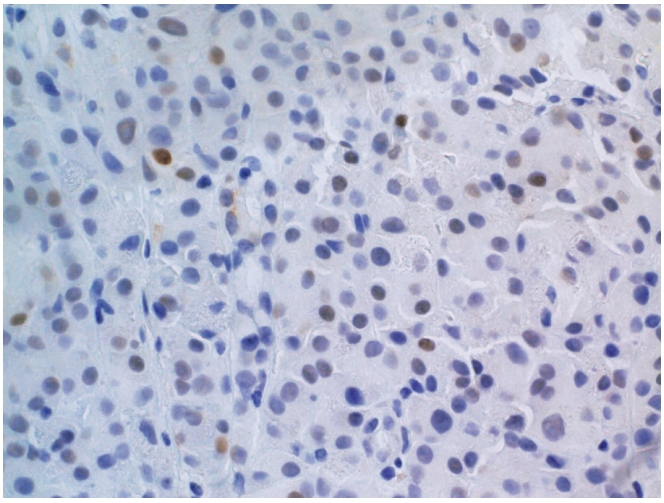

FIGURE 4. Nonfunctioning WDNET of the pancreas. CDX-2 immunoreactivity is seen in a limited percentage of nuclei with moderate to faint staining intensity.

RESULTS

Normal Tissues

In normal tissues, CDX-2 was expressed in the nuclei of almost all intestinal epithelial cells from the duodenum to the rectum, including intestinal endocrine cells as demonstrated by double immunohistochemical staining (Fig. 1). Normal gastric mucosa was devoid of CDX-2 immunoreactive cells, with the exception of single NE cells in the fundic glands. No reactivity was observed in all other tested endocrine/NE tissues, including pancreatic insulae.

WDNET

In WDNET, CDX-2 was expressed at high levels in all ileal and appendiceal lesions with intense nuclear and moderate cytoplasmic reactivity (Fig. 2A). In some cases, dot-like paranuclear staining was also observed (Fig. 2B). CDX-2 immunoreactivity in NE cell hyperplasias of the stomach (Fig. 3), WDNETs from the stomach, duodenum, and rectum was usually weak and restricted to a limited percentage of cells. Among pancreatic WDNETs, CDX-2 was seen in one third of nonfunctioning tumors, usually with a low percentage of immunoreactive nuclei and faint staining intensity (Fig. 4); no reactivity was seen in functioning tumors. CDX-2 immunoreactivity was more frequently observed in pancreatic WDNET with metastatic disease ($P = 0.002$, Table 2).

No CDX-2 reactivity was seen in NE cell hyperplasias of bronchial mucosa and in lung tumorlets, as well as in all lung WDNETs. No reactivity was observed in paragangliomas (6 cases), pheochromocytomas (4 cases), cortical adenoma (1 case) of the adrenal gland, thyroid (3 follicular, 7 papillary, and

TABLE 2. CDX-2 Expression in Pancreatic NE Tumors, According to the Metastatic Behavior of the Lesions (50 Cases With Complete Clinicopathologic Data)

	CDX-2-Positive			
	N	Intensity Range	Range	CDX-2-Negative
Nonmetastatic tumors (31)	2	2	90	29
Metastatic tumors (19)	9	1–3	5–90	10
P				0.002

2 medullary carcinomas), and parathyroid (2 adenomas) neoplasms.

High-grade NE Tumors

CDX-2 was expressed at high levels in the majority (13 of 16 cases, 81%) of intestinal poorly differentiated NECs. A variable percentage of CDX-2 reacting cells was seen also in 16 of 41 (39%) NECs of other sites, without an apparent relation with the site of origin (Table 3; Fig. 5). Fifty-one NEC cases were also evaluated for TTF-1 expression (Table 4). TTF-1 was observed in 3 of 13 (23%) gastrointestinal tumors, in 12 of 23 (52%) nongastrointestinal, nonpulmonary tumors, and in 9 of 13 (69%) lung NECs. Inappropriate expression of these gene products, ie, expression in tumors deriving from organs normally devoid of CDX-2 and/or TTF-1, was observed in 25 of 51 (49%) cases (Table 3).

Metastatic NE Tumors

In the 17 paired samples of primary and metastatic lesions analyzed, the pattern of immunoreactivity was similar in both sites. Strong and diffuse nuclear and cytoplasmic CDX-2 immunoreactivity was limited to metastatic ileal WDNETs (100% of cases); intermediate/low levels of staining were seen in one of six pancreatic well-differentiated carcinomas, in the single case of pancreatic poorly differentiated carcinoma (2+ in 30%), and in two gastrinomas from stomach and duodenum (1+ in 20% of the cells).

TABLE 3. CDX-2 Expression in NEC of Different Organs

		CDX-2-Positive			
Organs and Tumors	**Total No. of Cases**	**No. of Cases**	**Intensity Range**	**% of Positive Cells (range)**	**Pattern of Staining**
Lung					
Large cell NE carcinoma	8	5	1–3	20–60	N
Small cell lung carcinoma	8	1	3	30	NC
Stomach					
NEC	7	6	2–3	10–90	N/NC
Duodenum					
NEC	1	1	1	10	N
Ileum					
NEC	1	1	3	90	NC
Colon					
NEC	5	5	2–3	60–80	NC
Rectum					
NEC	2	0			
Liver					
NEC	1	1	2	10	N
Bladder					
NEC	10	4	1–3	5–70	N
Uterus					
NEC	3	2	2–3	20–90	N
Salivary gland					
NEC	3	1	2	20	N
Prostate					
NEC	5	2	1–2	20–40	N
Breast					
NEC	3	1	2	60	N
Endocrine ductal carcinoma	1	0			
Skin					
Merkel carcinoma	15	1	2	30	N

N, nuclear reactivity; NC, nuclear and cytoplasmic reactivity.

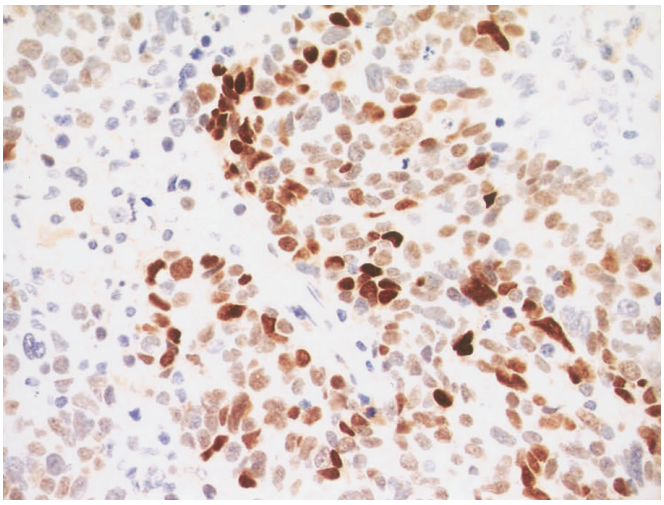

FIGURE 5. High-grade NE carcinoma of the bladder with prominent CDX-2 immunoreactivity.

Fine Needle Aspiration Samples of Hepatic Metastases

CDX-2 immunoreactivity was readily identified in all fine needle aspiration biopsies of ileal WDNETs (Fig. 6). Weak and focal staining was present in a single case of pancreatic endocrine carcinoma. No reactivity was seen in the remaining samples.

CDX-2 mRNA Expression

CDX-2 mRNA was expressed in the two samples of ileal WDNETs and in a colon adenocarcinoma used as positive control (Fig. 7). CDX-2 mRNA was not detectable in two pancreatic and one lung WDNET (Fig. 7). Gsα mRNA levels were constant in all tumors analyzed. mRNA results correlated with the CDX-2 expression at the immunohistochemical level.

DISCUSSION

Our study shows that CDX-2 is expressed in normal endocrine cells of the intestinal tract. We also demonstrate that CDX-2 is expressed in all primary and metastatic WDNET of the ileum and appendix, and in a subset of gastric, colorectal, and pancreatic WDNETs. The absence of CDX-2 in primary and metastatic WDNET of other sites suggests that CDX-2 expression may be used as a marker when the origin of a metastatic WDNET has to be determined. In addition, we observed CDX-2 expression in most NECs of the gastrointestinal tract but, surprisingly, also in a significant subset of NEC of other sites.

CDX-2 plays an important role in proliferation and differentiation of intestinal epithelial cells, where it is normally expressed throughout embryonic and postnatal life. The expression of CDX-2 in enterocytes, goblet, and Paneth cells as well as in NE cells of the human intestine may be interpreted in the light of their hypothesized origin from a common totipotent stem cell.[7,20] Moreover, the expression of CDX-2 in all NE cells of the gastrointestinal tract in contrast to the lack of expression in NE cells of other organs (eg, bronchial tree) is in keeping with the hypothesis that cells of the dispersed NE system originate from pluripotent cells that differentiate locally under the control of factors unique to a specific site or organ.[18]

Data on CDX-2 expression in human tumors are still limited: we and others recently showed that CDX-2 is ex-

TABLE 4. Combined CDX-2 and TTF-1 Expression Patterns in 51 High-Grade NE Tumors

Site	No. of Cases	CDX-2+ TTF-1+	CDX-2+ TTF-1−	CDX-2− TTF-1+	CDX-2− TTF-1−	Inappropriate Expression
Small intestine	1	0	1	0	0	
Colon/rectum	7	0	5	1	1	1
Stomach	4	1	3	0	0	1
Duodenum	1	1	0	0	0	1
Liver	1	1	0	0	0	1
Bladder	10	2	2	0	6	4
Breast	3	0	1	1	1	2
Uterus	3	2	0	0	1	2
Salivary gland	3	0	1	1	1	2
Prostate	5	2	0	3	0	5
Lung small cell carcinoma	5	0	1	3	1	1
Lung large cell NE carcinoma	8	4	1	2	1	5
Total	51	13	15	11	12	25/51

Note: Cases are categorized as positive if the markers are expressed in at least 5% of tumor cells.

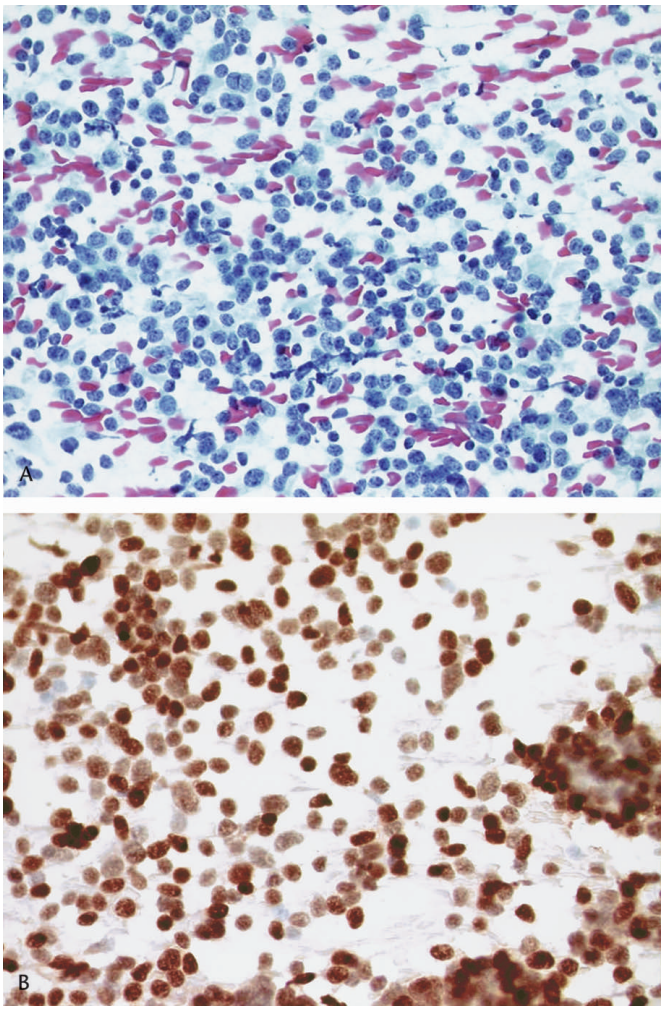

FIGURE 6. Fine needle aspiration sample of a metastatic ileal WDNET in the liver. The cells show moderate pleomorphysm, an ill-defined cytoplasm (A), and intense nuclear CDX-2 immunoreactivity (B).

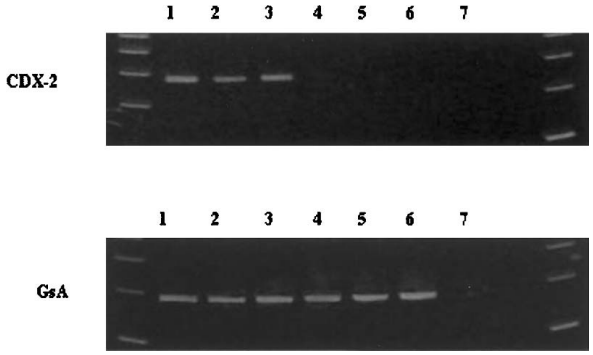

FIGURE 7. CDX-2 and Gsα mRNA expression in NE tumors. CDX-2 mRNA was expressed in the two samples of ileal WDNETs (lanes 2 and 3) and in the colon adenocarcinoma used as positive control (lane 1). CDX-2 mRNA was not detectable in two pancreatic and one lung WDNET (lanes 4–6). Gsα mRNA levels were constant in all tumors analyzed.

pressed in almost all colorectal adenocarcinomas and in a subset of gastric, pancreatic, and ovarian cancers, while it was not expressed in a large series of human tumors, including lung neoplasms.[2,11,15,19,23] This restricted pattern of expression, which is a characteristic of several other homeobox gene products, such as TTF-1, is very useful in differential diagnosis in a variety of settings, including the evaluation of cytologic specimens.

In the present study, we expand the knowledge about the possible use of CDX-2 as a diagnostic marker in the setting of WDNET. Our results demonstrate that CDX-2 strong expression is a highly sensitive marker for the identification of WDNET originating from the small intestine and appendix. CDX-2 is highly effective both on histologic and cytologic specimens. CDX-2 is expressed at low levels also in a significant percentage of pancreatic WDNETs. This phenomenon must be kept in mind when dealing with a metastatic WDNET of unknown primary site. However, CDX-2 immunoreactivity in pancreatic WDNET tumors is usually weak and heterogeneous, limited to the nucleus, thus making this pattern of reactivity quite different from that observed in ileal and appendiceal WDNETs.

Interestingly, CDX-2 expression correlated with the functional and clinical behavior of pancreatic WDNET: it was not expressed in functioning and in the majority of nonmetastatic tumors, whereas it was observed in one third of nonfunctioning and in almost half of tumors with metastatic behavior. The possible biologic and clinical relevance of these findings is unknown and deserves further investigation.

CDX-2 can be added to the limited list of markers that can be used in the differential diagnosis of WDNET of unknown primary origin. This list includes, beside specific hormones, the product of another homeobox gene, TTF-1. TTF-1 has been considered specific for lung WDNET, although there are major discrepancies in the literature regarding its sensitivity.[9,10,13,16,21] CDX-2 in combination with TTF-1 may help to correctly differentiate intestinal from lung WDNET.

CDX-2 expression was observed also in the majority of gastric and intestinal NECs, but, unexpectedly, also in a significant percentage of NEC of other sites. CDX-2 expression in these nongastrointestinal tumors was considered inappropriate because the organs where these tumor originate do not normally express CDX-2, nor do these tumors have any morphologic or biologic known feature of intestinal differentiation. This inappropriate expression limits its diagnostic utility in this setting. This pattern of CDX-2 expression parallels the similar abnormal expression of TTF-1 in non-lung NECs.[13,17] The biologic significance of this inappropriate expression of both homeodomain proteins in NEC is at present unclear but suggests a complex deregulated expression of homeobox genes in NEC.[1]

In summary, our study expands the knowledge about the distribution of CDX-2 immunoreactivity in human neoplasms. In the setting of WDNET, strong nucleocytoplasmic reactivity is limited to tumors of the intestinal tract, while weak expression can be observed in subsets of aggressive pancreatic tumors. This restricted pattern of expression may have diagnostic value in the identification of the primary site of a metastatic WDNET. Conversely, a limited diagnostic role for CDX-2 is suggested in NEC because of its frequent inappropriate expression in NECs originating outside the gastrointestinal tract.

NOTE ADDED IN PROOF

Similar results on CDX-2 expression in NE cells and Tumors have been reported by La Rosa et al. (Virchows Archive, in press 2004). These Authors also underscore the relation between CDX-2 expression and the type of hormonal secretion of the NE cells and Tumors.

ACKNOWLEDGMENTS

We thank Lucia Tamis, Silvia Funes, Enzo Meggiolaro and Roberto Cairella for their skillful technical assistance.

REFERENCES

1. Abate-Shen C. Deregulated homeobox gene expression in cancer: cause or consequence? *Natl Rev Cancer*. 2002;2:777–785.
2. Barbareschi M, Murer B, Colby TV, et al. CDX-2 Homeobox gene expression is a reliable marker of colorectal adenocarcinoma metastases to the lungs. *Am J Surg Pathol*. 2003;27:141–149.
3. Barbareschi M, Pecciarini L, Cangi MG, et al. p63, a p53 homologue, is a selective nuclear marker of myoepithelial cells of the human breast. *Am J Surg Pathol*. 2001;25:1054–1060.
4. Bonner CA, Loftus SK, Wasmuth JJ. Isolation, characterization, and precise physical localization of human CDX1, a caudal-type homeobox gene. *Genomics*. 1995;28:206–211.
5. Burglin TR. *A Comprehensive Classification of Homeobox Genes*. New York: Sambrook and Tooze, 1994.
6. Cai Y, Banner B, Glickman J, et al. Cytokeratin 7 and 20 and thyroid transcription factor 1 can help distinguish pulmonary from gastrointestinal carcinoid and pancreatic endocrine tumors. *Hum Pathol*. 2002;32:1087–1093.
7. Cheng H, Leblond CP. Origin, differentiation and renewal of the four main epithelial cell types in the mouse small intestine: V. Unitarian theory of the origin of the four epithelial cell types. *Am J Anat*. 1974;141:537–561.
8. Drummond F, Putt W, Fox M, et al. Cloning and chromosome assignment of the human CDX-2 gene. *Ann Hum Genet*. 1997;61:393–400.
9. Fabbro D, di Loreto C, Stamerra O, et al. TTF-1 gene expression in human lung tumours. *Eur J Cancer*. 1996;32A:512–517.
10. Folpe AL, Gown AM, Lamps LW, et al. Thyroid transcription factor-1: immunohistochemical evaluation in pulmonary neuroendocrine tumors. *Mod Pathol*. 1999;12:5–8.
11. Fraggetta F, Pelosi G, Cafici A, et al. CDX-2 immunoreactivity in primary and metastatic ovarian mucinous tumours. *Virchows Arch*. 2003;443:7826.
12. Giordano TJ, Shedden KA, Schwartz DR, et al. Organ-specific molecular classification of primary lung, colon, and ovarian adenocarcinomas using gene expression profiles. *Am J Pathol*. 2001;159:1231–1238.
13. Kaufmann O, Dietel M. Expression of thyroid transcription factor-1 in pulmonary and extrapulmonary small cell carcinomas and other neuroendocrine carcinomas of various primary sites. *Histopathology*. 2000;36:415–420.
14. Lui VC, Li L, Sham MH, et al. CDX-1 and CDX-2 are expressed in human colonic mucosa and are down-regulated in patients with Hirschsprung's disease associated enterocolitis. *Biochim Biophys Acta*. 2001;1537:89–100.
15. Moskaluk CA, Zhang H, Powell SM, et al. Cdx2 protein expression in normal and malignant human tissues: an immunohistochemical survey using tissue microarrays. *Mod Pathol*. 2003;16:913–919.
16. Oliveira AM, Tazelaar HD, Myers JL, et al. Thyroid transcription factor-1 distinguishes metastatic pulmonary from well-differentiated neuroendocrine tumors of other sites. *Am J Surg Pathol*. 2001;25:815–819.
17. Ordonez NG. Value of thyroid transcription factor-1 immunostaining in distinguishing small cell lung carcinomas from other small cell carcinomas. *Am J Surg Pathol*. 2000;24:1217–1223.
18. Pearse AG, Takor T. Embryology of the diffuse neuroendocrine system and its relationship to the common peptides. *Fed Proc*. 1979;38:2288–2294.
19. Phillips RW, Frierson JH, Moskaluk CA. Cdx2 as a marker of epithelial intestinal differentiation in the esophagus. *Am J Surg Pathol*. 2003;27:1442–1447.
20. Rindi G, Ratineau C, Ronco A, et al. Targeted ablation of secretin-producing cells in transgenic mice reveals a common differentiation pathway with multiple enteroendocrine cell lineages in the small intestine. *Development*. 1999;126:4149–4156.
21. Sturm N, Lantuejoul S, Laverriere MH, et al. Thyroid transcription factor 1 and cytokeratins 1, 5, 10, 14 (34betaE12) expression in basaloid and large-cell neuroendocrine carcinomas of the lung. *Hum Pathol*. 2001;32:918–925.
22. Walters JR, Howard A, Rumble HE, et al. Differences in expression of homeobox transcription factors in proximal and distal human small intestine. *Gastroenterology*. 1997;113:472–477.
23. Werling RW, Yaziji H, Bacchi CE, et al. CDX-2, a highly sensitive and specific marker of adenocarcinomas of intestinal origin: an immunohistochemical survey of 476 primary and metastatic carcinomas. *Am J Surg Pathol*. 2003;27:303–310.

